

**FINAL REPORT OF AUTOPSY**  
**AME2-M3-02**

**DECEDENT:** Chloe Britt **Authorized by:** James E. Lee, CMEI Adams County

**Fax #:**

<b>Type of Death:</b>	<b>Rigor</b>	<b>Livor</b>
( X ) Violent or Unnatural ( ) Unattended by a physician	(X) Jaw ( X ) Arms	Color : Purple
( ) Sudden in apparent health	(X) Neck ( X ) Chest	( ) Ant. ( X ) Posterior
( ) Unusual/Suspicious ( ) Custody of law	(X) Back ( X ) Abdomen	( ) Lateral
( ) Possibly Drug Related ( ) Public Health	( X ) Legs	Fixed

**Body Identified by:** Permit for autopsy by CMEI James Lee

**Persons present at autopsy:** Victor Beckley, Deane; Jimmy Roberts, CMEI Rankin County, Delrick Charleston, Morgue Attendant, Randolph Scott, CMEI Leake County, and the Prosector

\*\*\*\*\*

**AGE:** 6 months **RACE:** Caucasian **SEX:** Female **LENGTH:** 66.2 cm **WEIGHT:** 9.15 kilograms.  
**EYES:** Blue **PUPILS:** R 0.4 /L 0.4 **HAIR:** Brown **BODY HEAT:** Absent ; **SCARS & TATTOOS:** See

**Diagrams & External Exam**

\*\*\*\*\*

**CLOTHING:**

White Diaper

Released to : Released with remains

\*\*\*\*\*

**PERSONAL EFFECTS:**

**TRANSPORT INFO:** Morgue #: 31130 ; Driver - Tom Beard ; Company: Mississippi Mortuary Services  
Date of transport - 21 February, 2002 ; Time: 154 PM hours

\*\*\*\*\*

**EVIDENCE TO STATE CRIME LAB:**

**CRIME LAB CASE #:** Not assigned at time of Provisional

2 gray top tubes of blood, 1 gray top tube of vitreous, 1 red top tube of blood, 1 purple top tube of blood

**TRACE EVIDENCE TO STATE CRIME LAB:**

**Sexual Assault Kit**

**CAUSE OF DEATH:** Consistent with Shaken Baby Syndrome

**MANNER OF DEATH:** Consistent with homicide

The facts stated herein are true and correct to the best of my knowledge and belief:

22 February, 2002; 1850 hours

  
\_\_\_\_\_  
STEVEN T. HAYNE, M. D.  
PATHOLOGIST

**DATE & TIME OF AUTOPSY**

**EXHIBIT**  
**"D"**

AME2-M3-02

GENERAL:

The postmortem examination is requested by James Lee, Coroner Medical Examiner Investigator of Adams County. The request for the postmortem examination is made in that the decedent, Chloe Britt, died a violent death. The request for the postmortem examination is in compliance with the Coroner's Reorganization Act of 1986.

The postmortem examination is conducted at the Rankin County Morgue in Pearl, Mississippi, at 1850 hours on 22 February, 2002. The remains are identified as those of Chloe Britt by James Lee, CMEI Adams County. Individuals present and attending the postmortem examination are listed in detail on the front page of this report.

The decedent is a Caucasian female appearing to be the approximate recorded age of 6 months years. Clothing, valuables and jewelry are listed in detail on the front page of this report. The clothing is removed prior to the external and internal examinations. The clothing are released with the remains. The height, weight, and the presence or absence of rigor and livor mortis is listed in detail on the front page of this report.

TOXICOLOGY:

Two gray-topped tubes of blood and one gray topped tube of vitreous fluid are submitted to the Mississippi State Crime Laboratory under chain of custody for toxicological analysis. The final report reveals the presence of lidocaine and Trimethoprim in the blood specimen. The ethyl alcohol screen is pending at the time of the postmortem protocol. If and when received and if significant abnormalities are identified an addendum will be issued to the report.

SEROLOGY:

One red-topped tube of ventricular heart blood is submitted to the Mississippi State Crime Laboratory under chain of custody for serological analysis. The final report is pending.

DNA STUDIES:

One purple-topped tube of ventricular heart blood is co-submitted with the previously identified red-topped tube of ventricular heart blood to the Mississippi State Crime Laboratory under chain of custody for DNA analysis if and when requested by the Coroner's Office.

SPECIAL STUDIES:

A sexual assault kit is employed to collect samples in the usual and prescribed manner. The sexual assault kit is transferred to the custody of the Mississippi State Crime Laboratory under chain of custody for processing. The final report reveals the absence on serological evaluation for the presence of semen on the oral swab, vulvar swabs, vaginal swabs, and rectal swabs. Full body radiographs are performed. Upon development of the radiographs no acute fractures are identified. The radiographs are retained at the Rankin County Morgue.

AME2-M3-02

PHOTOGRAPHIC DOCUMENTATION:

During the course of the post-mortem examination photographic documentation of the remains is performed. The photographs are submitted to the District Attorneys Office with a copy of the postmortem protocol.

NOTIFICATION OF THE CORONER:

Upon completion of the external and internal examinations, CMEI James Lee is faxed a Provisional Report of Autopsy appraising as to the preliminary cause and manner of death.

BODY ORGANS:

Representative sections of the major body organs are retained for microscopic analysis. The remaining and preponderance of the body tissues are returned to the body cavities

INTERNAL EXAMINATION:

The body is opened via the usual "Y" incision and subcutaneous adipose tissue over the chest wall is noted to measure to a depth of 0.4 cm and over the abdomen to a depth of 0.5 cm. The anterior right and left ribs are reflected en block with the sternum in the usual manner. A small amount of clear wetting fluid is present within the right and left pleural cavities. No visceral and parietal pleural adhesions are identified. The right lung is noted to have a mass of 193rams and the left lung is noted to have a mass of 193 grams. The lungs are serially cross sectioned and a large amount of serosanguineous fluid exudes from the cut surfaces. Examination of the cross sections of the lungs fail to reveal evidence of thromboembolic material, tumor, and/or infection.

The pericardial sac is opened, and a small amount of clear wetting fluid is present within the luminal space. The take off of the great vessels is unremarkable. The heart is noted to have a mass of 38 grams and external examination of the heart is within normal limits. The coronary arteries are serially cross sectioned and are within normal limits. The heart is serially cross sectioned and the right ventricle measures up to 0.3 cm in thickness and the left ventricle measures up to 0.8 cm in thickness. Examination of the cross sections of the heart fails to reveal evidence of acute or remote infarction. The four cardiac valves are unremarkable and no evidence of congenital heart disease is found. The aorta is examined through its entire course and reveals no significant abnormalities.

The abdominal cavity is opened and a small amount of clear wetting fluid is present within the luminal space.

The vertebral column and rib cage are palpated and visually inspected and no antemortem fractures are identified of an acute nature.

## AME2-M3-02

The liver assumes its usual right upper quadrant location and is noted to have a mass of 198 grams. The capsule is intact and no subcapsular contusions are appreciated. The liver is serially cross sectioned and a large amount of serosanguineous fluid exudes from the cut surfaces. Examination of the cross sections of the liver reveals no significant abnormalities. The gallbladder is found on the inferior surface of the liver and is noted to measure 3 cm in length and contains approximately 0.5 cc of bile. No gallstones are identified. The mucosal surface of the gallbladder is unremarkable. The biliary tree is patent to the duodenum.

The spleen assumes its usual left upper quadrant abdominal location and is noted to have a mass of 19 grams. The capsule is intact and no subcapsular contusions are appreciated. The spleen is serially cross sectioned and a moderate amount of serosanguineous fluid exudes from the cut surfaces. Examination of the cross sections of the spleen reveal the Malpighian corpuscles to be of normal size and number. A section of vertebral bone marrow reveals no gross abnormalities. Mesenteric lymphadenopathy is identified.

The right and left kidneys assume their usual retroperitoneal location and each is noted to have a mass of 36 grams. The capsules strip with ease revealing changes consistent with fetal lobulation. The kidneys are serially cross sectioned and a moderate amount of serosanguineous fluid exudes from the cut surfaces. The calyces are unremarkable. The ureters are single bilaterally and patent to the urinary bladder. A catheter is present within the urinary bladder. The mucosal surface of the urinary bladder is unremarkable. Examination of the corpus uterus and cervix reveal no significant abnormalities and are normal for age.

The esophagus is unremarkable. The stomach is empty. The mucosal surface is unremarkable. The small bowel, vermiform appendix and large bowel are essentially unremarkable. Well formed stool is present within the luminal space of the large bowel. A contusion of the anus is noted and a section is taken for microscopic review. The mesentery and omentum are unremarkable. No adhesions are identified to involve the organs of the abdominal cavity.

The pancreas assumes its usual retroperitoneal location and is noted to have a mass of approximately 12 grams. The tan structure is serially cross sectioned and no abnormalities are identified. The right and left adrenal glands assume their usual suprarenal location and each is noted to have a mass of approximately 3 grams. The structures are serially cross sectioned and no abnormalities are identified. The thyroid gland assumes its usual location on the anterior surface of the trachea and is noted to have a mass of approximately 3 grams. The structure is serially cross sectioned and no abnormalities are identified.

The scalp is reflected and a diffuse subarachnoid hemorrhage is identified. The calvarium is removed and approximately 30 cc of blood is identified within the subdural space and a subdural hemorrhage is identified to involve the right and left cerebral hemispheres. A multifocal cephalohematoma is identified that measures up to 3 cm. The right and left eyes are enucleated. Upon serially cross sectioning the eyes changes consistent with retinal hemorrhage are identified. Periocular nerve hemorrhage is noted bilaterally. The brain has a mass of 749 grams. The Circle of Willis and supportive vascular structures are

AME2-M3-02

unremarkable. The ventricular system is unremarkable. The dura is stripped and no evidence of fracture to involve the calvarium or base of the skull is found.

EXTERNAL EXAMINATION:

- A. HEAD & NECK: Examination of the scalp reveals the scalp to be covered with blonde hair. The eyes are blue, the sclera clear and the pupils are fixed bilaterally at 0.4 cm. No evidence of remote injury is appreciated to involve the head or neck. No evidence of acute medical intervention is identified. A 6 cm contusion is identified over the posterior aspect of the scalp. Contusions are identified over the forehead that measure up to 2 cm. A 0.5 cm contusion on the furrow of the bridge of the nose is identified. A 1 cm contusion is identified over the upper lip. An intra-oral examination reveals a 0.5 cm tear of the frenulum. The facial bone are palpated and no fractures are identified.
- B. RIGHT UPPER EXTREMITY: Examination of the right arm, forearm, and hand reveals no evidence of remote injury. Two 0.1 cm iatrogenic puncture sites are identified over the proximal anterior surface of the forearm. The fingernails are intact and no tears to the fingernails are identified and no foreign tissue is identified underneath the fingernails. No acute contusions, abrasions, or lacerations are identified to involve the extremity. The long bones are palpated and no fractures are identified.
- C. LEFT UPPER EXTREMITY: Examination of the right arm and forearm reveal no evidence of remote injury. An intravenous catheter is inserted over the dorsal surface of the hand and held in apposition with tape. The fingernails are intact and no tears to the fingernails are identified and no foreign tissue is identified underneath the fingernails. No acute contusions, abrasions, or lacerations are identified to involve the extremity. The long bones are palpated and no fractures are identified.
- D. RIGHT LOWER EXTREMITY: Examination of the right leg and foot reveals the presence of contusions identified over the anterior surface of the thigh that measure up to 2 cm. No evidence of remote injury is appreciated. Two 0.1 cm iatrogenic puncture sites are identified over the anterior surface of the thigh that measure up to 2 cm. No evidence of remote injury is appreciated. Two 0.1 cm iatrogenic puncture sites are identified over the instep of the foot and a 0.3 cm iatrogenic puncture site is identified adjacent to the heel of the foot. The long bones are palpated and no fractures are identified.
- E. LEFT LOWER EXTREMITY: Examination of the left leg and foot reveals no evidence of remote injury. No evidence of acute medical intervention is appreciated. A 4 cm contusion is identified over the anterior surface of the thigh. The long bones are palpated and no fractures are identified.
- F. CHEST & ABDOMEN: Examination of the chest and abdomen reveals no evidence of remote injury. The external genitalia is unremarkable. A urinary catheter is inserted in the usual manner. No acute contusions, abrasions, or lacerations are identified to involve the chest or abdomen.

AME2-M3-02

- G. BACK: Examination of the back reveals no evidence of remote injury. No evidence of acute medical intervention is appreciated. No acute contusions, abrasions, or lacerations are identified to involve the back.

MICROSCOPIC ANALYSIS:

- A. RESPIRATORY SYSTEM: Sections of lung reveal pulmonary vascular congestion with focal atelectasis. Evidence of infection, tumor, and/or thromboembolic phenomenon is not appreciated to involve the cross sectioned segments of the lungs reviewed microscopically. A section of trachea is unremarkable.
- B. CARDIOVASCULAR SYSTEM: Sections of myocardium are unremarkable. Evidence of inflammation or fibrosis is not appreciated. A section of coronary artery is unremarkable as is a section of aorta.
- C. HEPATOBILIARY SYSTEM: A section of liver reveals acute congestion. Evidence of acute or chronic hepatitis is not seen. The limiting plate is intact. No evidence of biliary stasis is appreciated. No evidence of focal necrosis is found. A section of gallbladder reveals autolytic change.
- D. RETICULOENDOTHELIAL SYSTEM: A section of spleen reveals acute congestion and the germinal centers are unremarkable. A section of mesenteric lymph node reveals reactive lymphoid hyperplasia. A section of vertebral bone marrow reveals normal cellularity in maturation and no atypical cells are identified for age. A section of thymus is unremarkable.
- E. GENITOURINARY SYSTEM: Sections of kidney reveal acute congestion. The glomeruli, interstitium, tubules, and blood vessels are unremarkable. A section of urinary bladder is unremarkable.
- F. GASTROINTESTINAL SYSTEM: Sections of esophagus, stomach, small bowel, vermiform appendix, and large bowel are unremarkable. A section of anus reveals submucosal hemorrhage.
- G. ENDOCRINE SYSTEM: Sections of pancreas, adrenal gland and thyroid gland are essentially unremarkable.
- H. CENTRAL NERVOUS SYSTEM: Sections of cerebral cortex reveal subarachnoid hemorrhage as does sections of cerebellum and brainstem. Changes of mild cerebral edema are concurrently identified. Sections of enucleated eyes reveals bilateral retinal hemorrhage as well as perioptic nerve hemorrhage bilaterally.

CAUSES OF DEATH & PATHOLOGIC FINDINGS:

- A. IMMEDIATE CAUSE OF DEATH:
1. Changes consistent with shaken baby syndrome and closed head injuries.

AME2-M3-02

B. ACUTE TRAUMATIC INJURIES:

1. Cephalohematoma.
2. Subdural hemorrhage.
3. Subarachnoid hemorrhage.
4. Retinal hemorrhage, bilateral.
5. Contusions of the forehead.
6. Contusion of the bridge of the nose.
7. Contusion of the upper lip.
8. Tear of the frenulum.
9. Contusion of the posterior aspect of the scalp.
10. Contusion of the anterior surface of the right thigh.
11. Contusion of the anterior surface of the left thigh.

C. OTHER PATHOLOGIC FINDINGS:

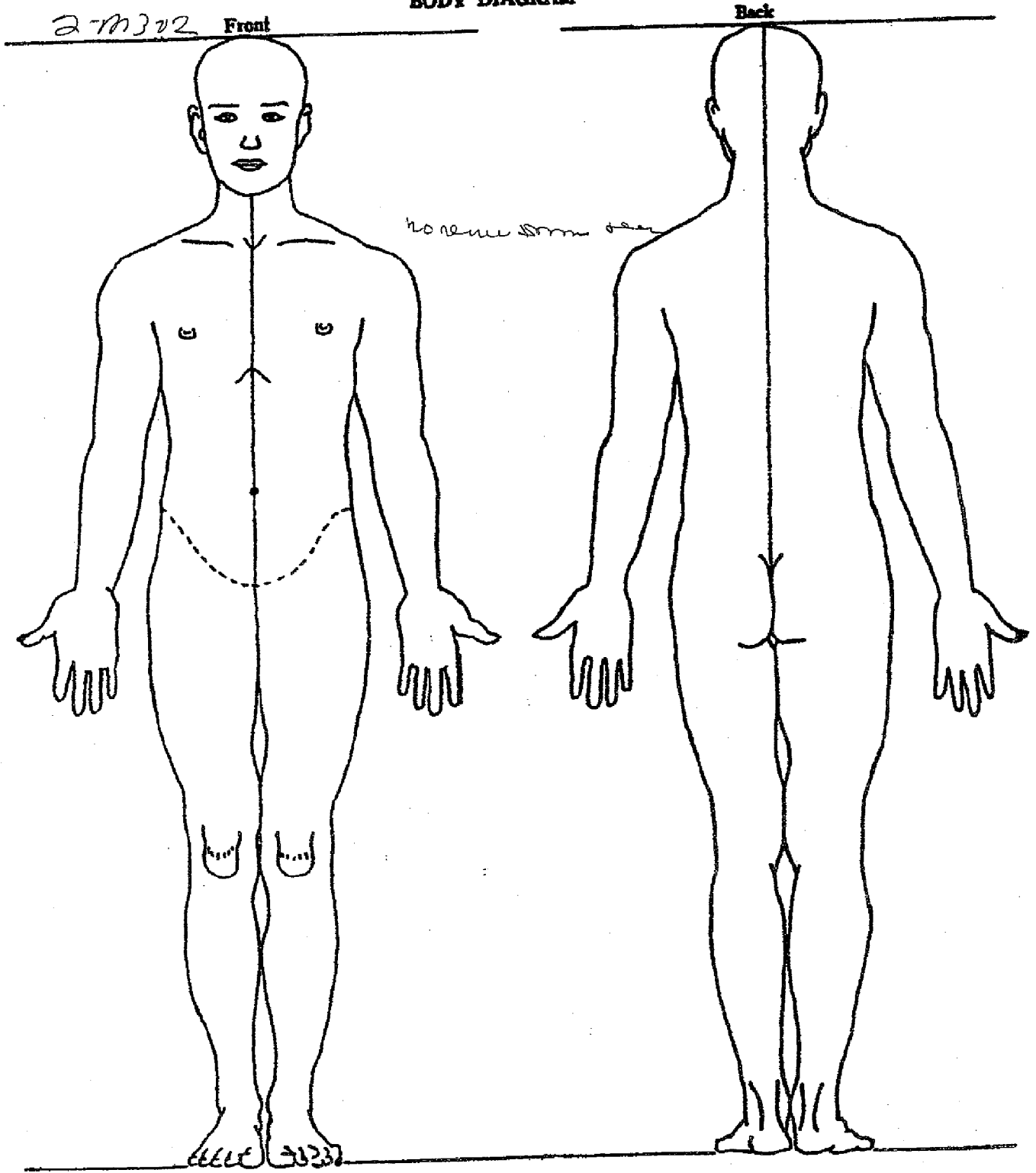
1. Pulmonary vascular congestion and edema.
2. Atelectasis of the lungs.
3. Acute hepatic congestion.
4. Acute splenic congestion.
5. Reactive lymphoid hyperplasia of the perihilar lymph nodes.
6. Acute renal congestion, bilateral.
7. Persistence of fetal lobulation of the kidneys.

MANNER OF DEATH: Homicide.

DISCUSSION OF THE CASE: The decedent was noted to succumb secondary to a combination of closed head injury and changes consistent with Shaken Baby Syndrome. The manner of death is ruled homicide.

**Rankin County Morgue**  
**150 Concourse Drive**  
**Pearl, Mississippi**

**BODY DIAGRAM**



Decedent's  
Height \_\_\_\_\_ inches

Name Choe Britt  
Time 22:00



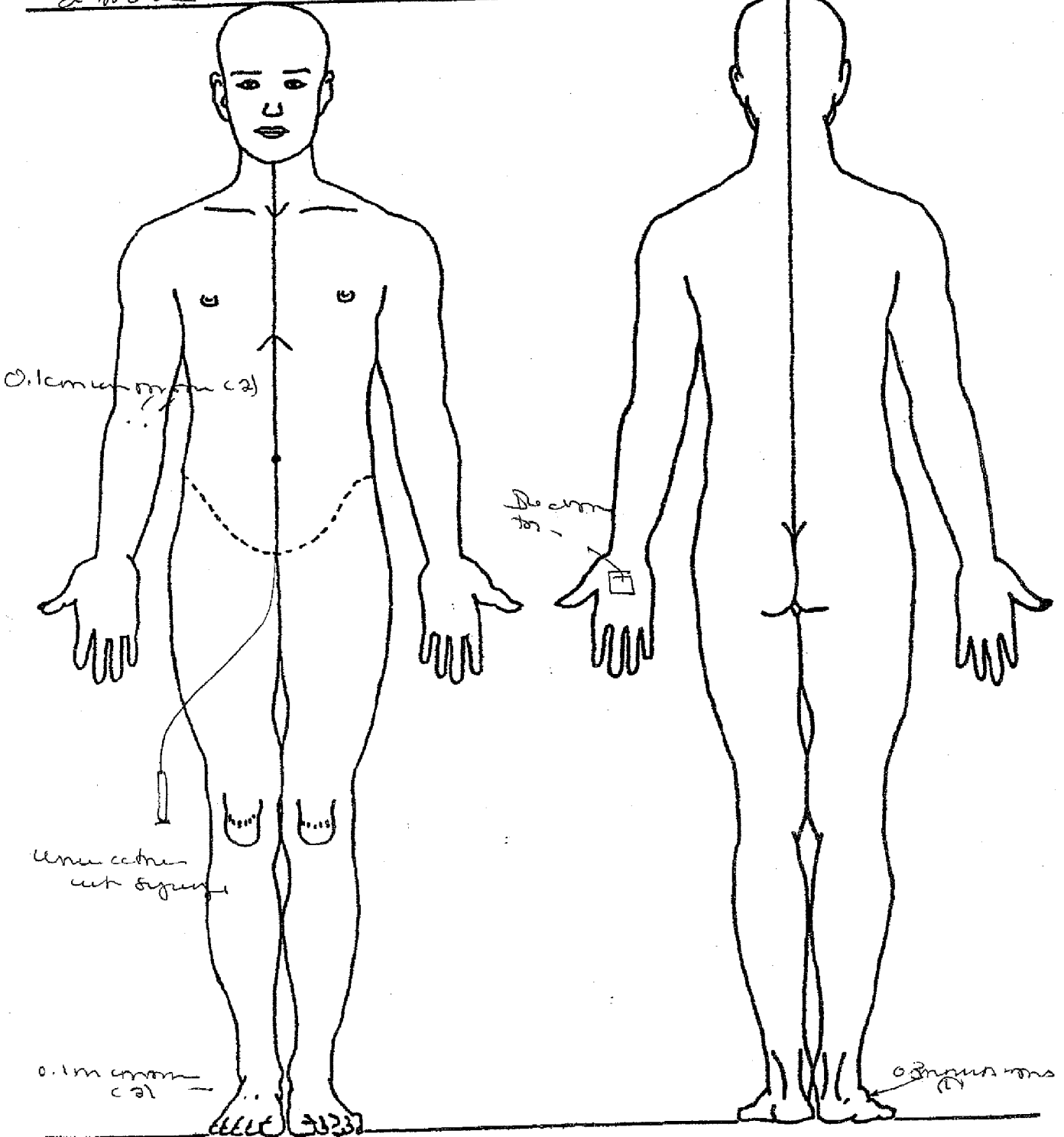
Rankin County Morgue  
150 Concourse Drive  
Pearl, Mississippi

BODY DIAGRAM

20302

Front

Back



Decedent's Height \_\_\_\_\_ inches

Name Chloe Britt  
Date 12/22/12

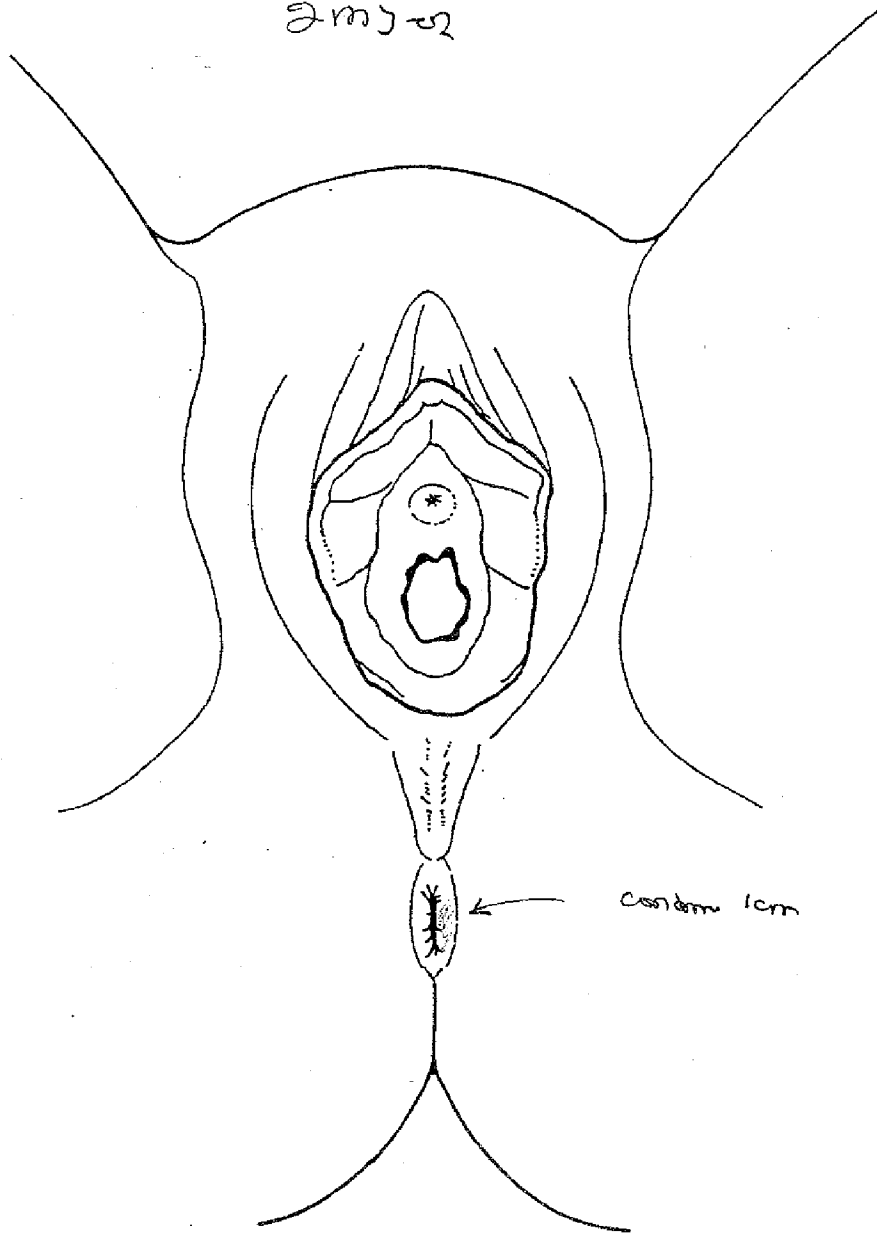
Rankin County Morgue

150 Concourse Drive

Pearl, Mississippi

PERINEUM - FEMALE

2m3-2



Name Chloe Burt

Case No. 2m3-2

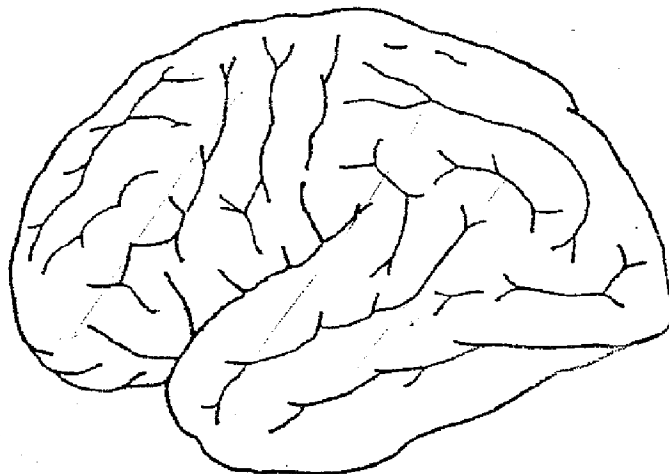
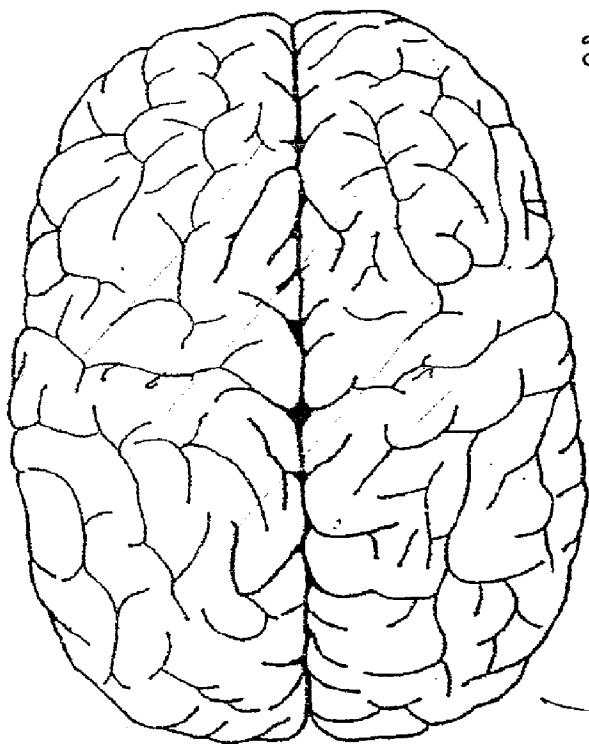
Date 27 Nov

150 CONTOUR DRAW

### Pearl, Mississippi

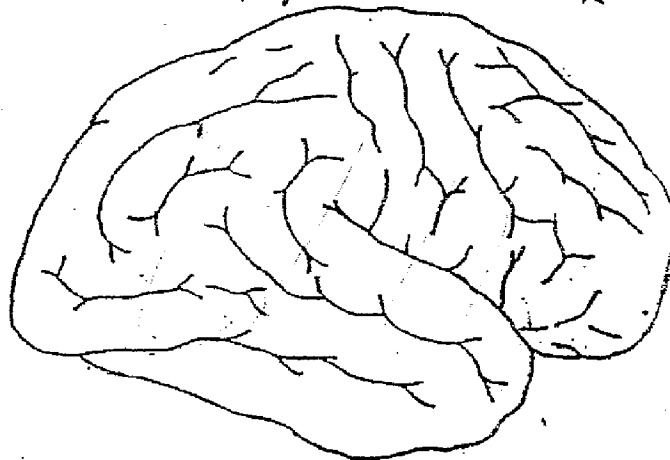
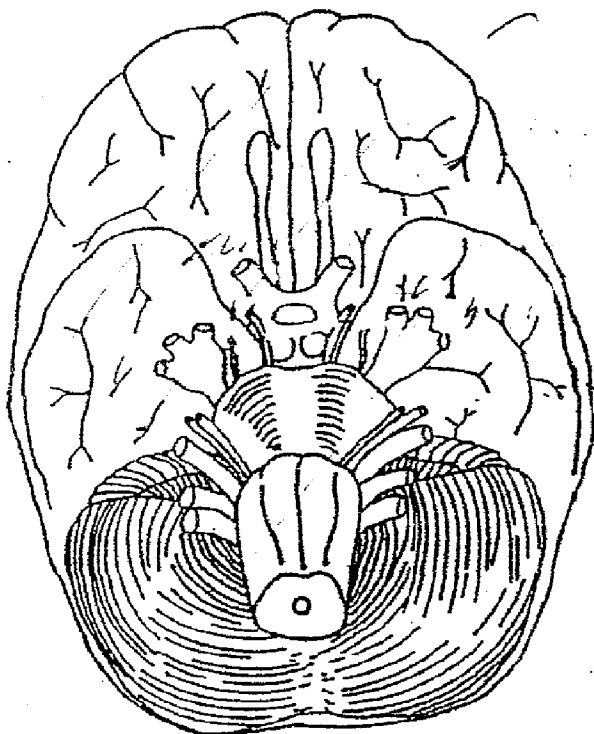
### BRAIN - SUPERIOR, INFERIOR, AND LATERAL VIEWS

2m3-22



diff. sulci & gyri

was on a ceiling car  
w/pe of cranium base



2wce hemis = 30c km

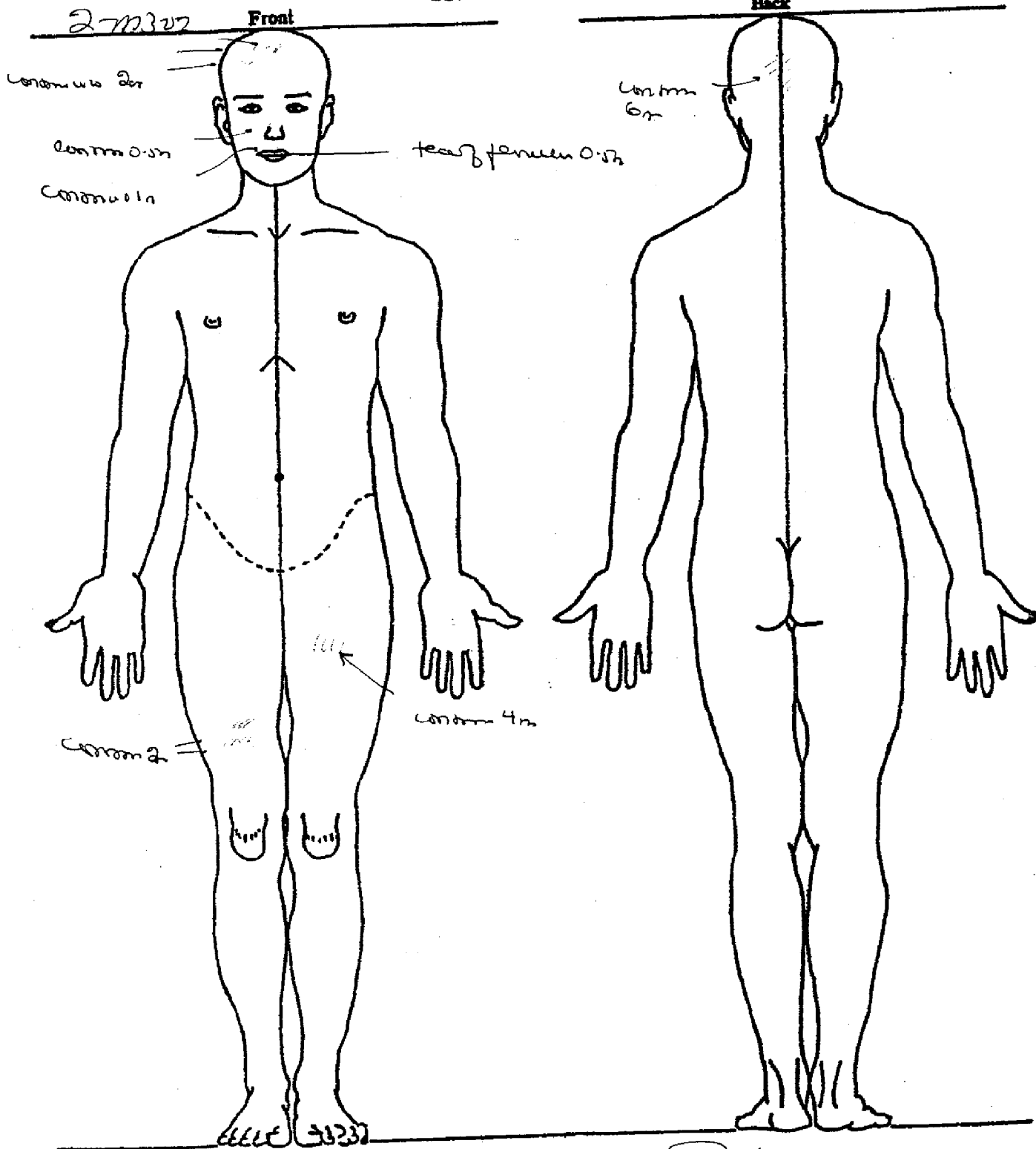
Name Chloe Pined

Case No. 2m3-22

2008

**Rankin County Morgue**  
**150 Concourse Drive**  
**Pearl, Mississippi**

**BODY DIAGRAM**



Decedent's Height \_\_\_\_\_ inches

Name Robert J. 220m